Philippe Bellemère, Marion Aribert, Hussein Choughri, Marc Leroy, Etienne Gaisne

Published in J Wrist Surg 2018

INSTITUT DE LA MAIN NANTES ATLANTIQUE
CLINIQUE JEANNE D'ARC

CHU GRENOBLE ALPES

SOO 2018
28 – 29 – 30 juin
Rennes

Introduction (1/2)

- **Pisiform = Patella-like bone**
  - Acts as a lever arm for FCU action
  - Stabilizes the first row
  - Protects ulnar nerve
  - Surounded by 9 tendons or ligaments
    ➔ Provide pisifom stability
  - Gliding « adaptable » motion
    - Proximo-distal
    - Ulno-radial

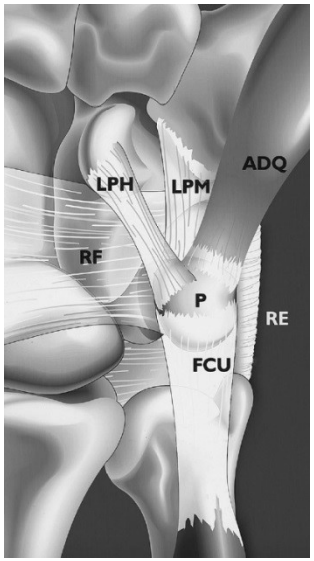

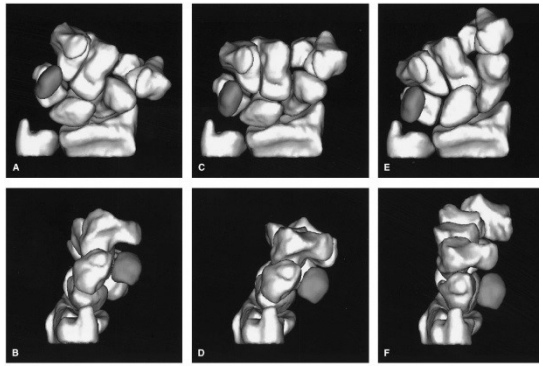

From Moojens and al. *JHS 2001; 26A:901-907*

- **PT joint arthritis treatment:**
  - Pisiformectomy = gold standard:
    - Alters proximal row kinematic
    - Reduces strength flexion and ROM extension
    - Uncomplete pain relief
    - Ulnar nerve syndrom
  - PT fusion : for high functional demand patient
    - More complications
    - Reduces ROM flexion and extension

Introduction (2/2)

- **Pyrocardan® implant:**
  - Spacer
  - Rectangular shape with 2 cylindrical concave surfaces opposed perpendicularly to one another
  - Pyrocarbon (mechanical property similar to cortical bone)
  - Already used in TM and STT joint

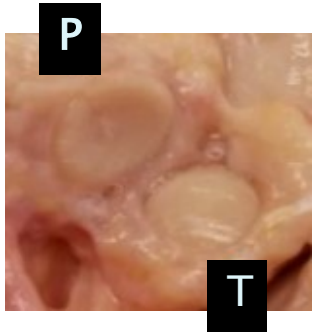

- Study objective:

  Propose a new surgical procedure preserving the pisiform

  ➔ Interposition arthroplasty of the PT joint with a pyrocarbon implant

  ➔ Report early results

a conflict of interest to disclose with
Wright medical company. Other
have nothing to disclose.

Material and method (1/2)

- **Surgical technic:**

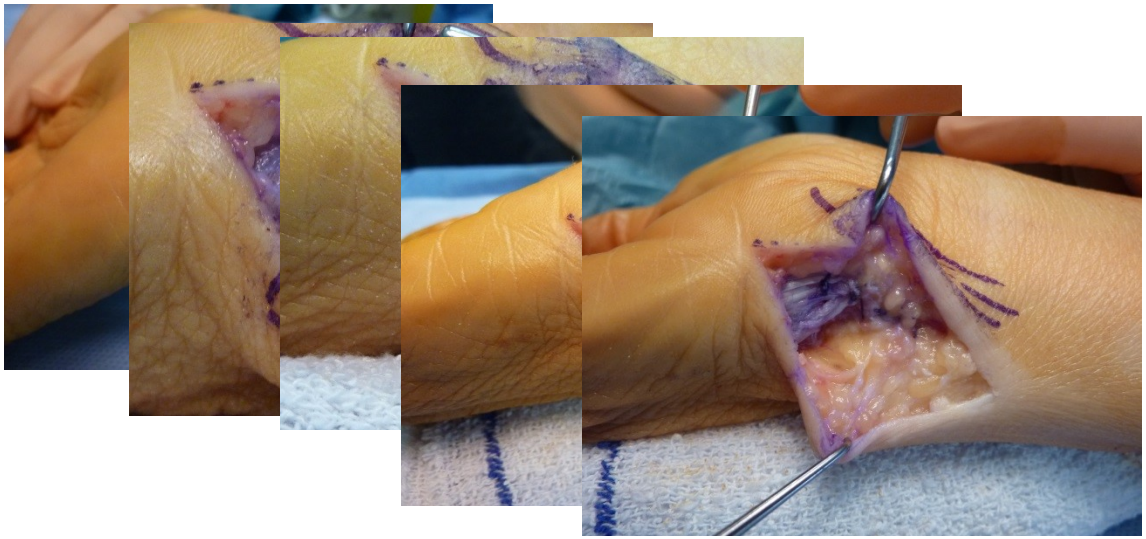

- **Postoperative care:**
  - Permanent splint for 2 weeks
  - Removable splint until the 4th week postoperavtive
  - No restriction after 6 weeks

Material and method (2/2)

- **Series: 8 patients**
  - 1 ♂ , 7 ♀
  - Mean age: 60 years old (51 to 74 years)
  - 4 dominant hand
  - 5 workers
  - Etiology :
    - Degenerative arthrosis : 7 cases
    - Posttraumatic arthrosis : 1 case
  - Indication:
    - Ulnar wrist pain with PT arthrosis
    - Failure of medical treatment

➔ **Follow-up: 2.5 years (0.9 to 4 years)**

- **Pre and postop evaluation:**
  - Pain VAS
  - Grip strength, ROM (F/E, U/R deviation)
  - PRWE, QuickDash, MWS
  - Patient satisfaction

- **Radiological postop evaluation:**
  - Pisotriquetral space (A)*
  - Pisohamatal distance (B)*
  - Pisiform motion (C)*
  - Fluroscopy kinematic on 3 cases

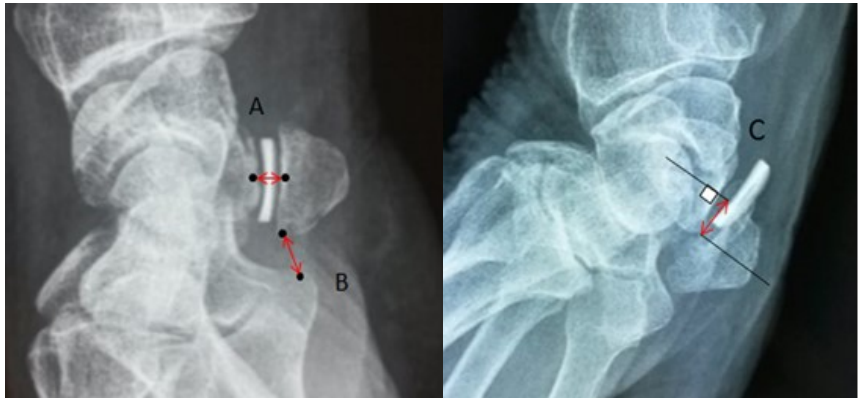

* Jameson and al Radio, J Hand Surg. Sept 2002

Results (1/2)

- **1 reoperation** after 1 month for proximal luxation of the implant
  - Implant repositioning
  - Proximal capsule reinforcement

onth postop 12 months postop

♂ 50 years
Domiant side
Postman biker

- VAS = 0
- F/E, UD/RD = 100% / Clt
- Grip = 45 kg (112.5% / Clt)
- Very satisfied
- MWS = 100
- QDASH = 13.6
- PRWE = 4

Results (2/2)

- Pain relief: – 5.4 points
  - VAS = 1.6 (7 preop)
    62.5% no pain
- ROM: unchanged
  - F/E : 98%/Clt
  - R/U deviation : 106%/Clt
- Grip strength: +3kg
  - Grip = 103%/Clt
- Radiography:

	Values at last follow-up	Normal values *
Piso-triquetral space : - neutral wrist - wrist flexion - wrist extension	1.4 mm ± 0.3 2.3 mm ± 1.1 1.4 mm ± 0.5	1.5 mm (1 to 2mm) 3.5 mm (2 to 6 mm) 1 mm (0 to 1.5 mm)
Pisiform excursion	5.1 mm ± 2.4	6 mm (3 to 10 mm)
Piso-hamatale space: - neutral wrist - wrist flexion - wrist extension	3.8 ± 2.2 mm - 0.8 ± 2.5 mm 4.6 ± 2.5 mm	7.5 mm (4 to 10 mm) 2 mm (- 1 to 6 mm) 8 mm (5 to 11 mm)

J Hand Surg. Sept 2002

- Patients satisfaction:
  - Very satisfied: 87.5%
  - Satisfied: 12.5%
- Functional scores:
  - MWS = 85
  - QuickDash = 20.5 (70 preop)
  - PRWE = 23 (78 preop)
- Return to work:
  - 1.6 month ± 0.9

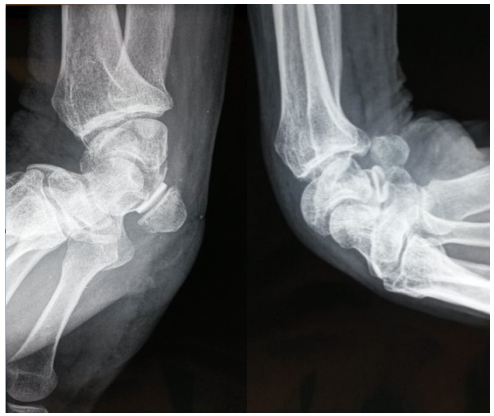

➔ **Normal position and motion of the pisiform with the arthroplasty**

Discussion

- Pyrocardan® interposition implant:
  - Preserves the pisiform ➔ anatomical and biomechanical interests
  - Non invasive (does not burn the bridges in failure case)
  - Good short term results on 8 cases

    ➔ Bigger series with longer follow-up are required

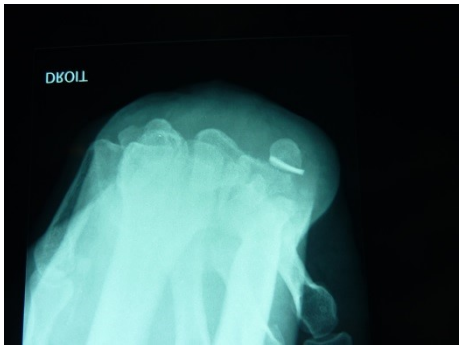

- **But pay attention to the proximal capsule**
  - **Weakest point of the joint +++, thin capsule or fenestration in nearly 75 %** (From Arya and al, *Bone Joint Surg* 2007;89-B:202-5)

    ➔ 1 early proximal luxation of the implant in our series

  - To avoid implant luxation
    - Check with a probe the proximal capsule
    - If fenestration or tear ➔ capsule reinforcement with Goretex CV O thread

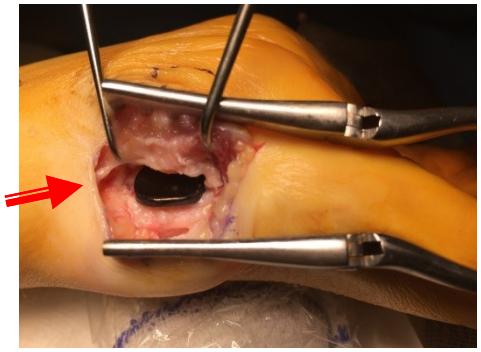

Références

1 Helal B. Racquet player's pisiform. Hand 1978;10(01):87-90

2 Carroll RE, Coyle MP Jr. Dysfunction of the pisotriquetral joint: treatment by excision of the pisiform. J Hand Surg Am 1985;10 (05):703-707

3 Palmieri TJ. Pisiform area pain treatment by pisiform excision. J Hand Surg Am 1982;7(05):477-480

4 Le Nen D, Saraux A, Yaacoub C, Hu W, Le Goff P, Lefevre C. Osteoarthritis of the pisiform-triquetral compartment. A review of eight cases of an underrecognized entity. Rev Rhum Engl Ed 1997;64(06):396-401

5 Saffar P, Duek C. Arthrose pisi-pyramidale. A propos de 13 cas et révision de la littérature. Chir Main 2002;21(02):107-112

6 Lam KS,Woodbridge S, Burke FD. Wrist function after excision of the pisiform. J Hand Surg [Br] 2003;28(01):69-72

7 Match RM. Nonspecific avascular necrosis of the pisiform bone: a case report. J Hand Surg Am 1980;5(04):341-342

8 Beckers A, Koebke J. Mechanical strain at the pisotriquetral joint. Clin Anat 1998;11(05):320-326

9 Arner M, Hagberg L. Wrist flexion strength after excision of the pisiform bone. Scand J Plast Reconstr Surg 1984;18(02): 241-245

10 O'Keefe KD, Werner FW, Boyette M, Palmer AK, Garcia-Elias M, Harley BJ. Effect of pisiform excision or pisotriquetral arthrodesis as a treatment for pisotriquetral arthritis: a biomechanical study. J Hand Surg Am 2013;38(10):1913-1918

11 Campion H, Goad A, Rayan G, Porembski M. Pisiform excision for pisotriquetral instability and arthritis. J Hand Surg Am 2014;39 (07):1251-1257.e1

12 van Eijzeren J, Karthaus RP. The effect of pisiformexcision onwrist function. J Hand Surg Am 2014;39(07):1258-1263

13 Bellemère P, Gaisne E, Loubersac T, Ardouin L, Collon S, Maes C. Pyrocardan implant: free pyrocarbon interposition for resurfacing trapeziometacarpal joint. Chir Main 2011;30:S28-S35

14 Gauthier E, Truffandier MV, Gaisne E, Bellemère P. Treatment of scaphotrapeziotrapezoid osteoarthritis with the Pyrocardan(®) implant: results with a minimum follow-up of 2 years. Hand Surg Rehabil 2017;36(02):113-121

15 Russo S, Bernasconi A, Busco G, Sadile F. Treatment of the trapeziometacarpal osteoarthritis by arthroplasty with a pyrocarbon

16 Serag[illegible]
tunnel release. J Ha[illegible]

17 Jameson BH, Rayan GM, A[illegible]
pisotriquetral joint and pisiform motion.[illegible]
27(05):863-869

18 Paley D, McMurtry RY, Cruickshank B. Pathologic conditions of the pisiform and pisotriquetral joint. J Hand Surg Am 1987;12 (01):110-119

19 Saraux A, Le Nen D. L'arthnose piso-triquétrale et ses diagnostics différentiels. Lett Rhumatol 2003;290:26-29

20 Rayan GM, Jameson BH, Chung KW. The pisotriquetral joint: anatomic, biomechanical, and radiographic analysis. J Hand Surg Am 2005;30(03):596-602

21 Pierre A, Le Nen D, Hu W, Dubrana F, Saraux A, Chaise F. Traitement des douleurs piso-triquétrales par exérèse du pisiforme: à propos de 15 cas. Chir Main 2003;22(01):37-42

22 Trail IA, Linscheid RL. Pisiformectomy in young patients. J Hand Surg [Br] 1992;17(03):346-348

23 Moreel P, UtrillasA, Le VietD. L'arthrose piso triquétrale. J Traumatol Sport 2005;22(02):102-106

24 Belliappa PP, Burke FD. Excision of the pisiform in piso-triquetral osteoarthritis. J Hand Surg [Br] 1992;17(02):133-136

25 Abrams R, Tontz W. Pisotriquetral arthrodesis as an alternative to excision for pisotriquetral instability in high-demand patients: a case report in a gymnast. J Hand Surg Am 2006;31 (04):611-614

Journal of Wrist Surgery Vol. 7 No. 1/2018

Pisotriquetral Pyrocarbon Arthroplasty Bellemère et al. 9

26 Singer G, Eberl R, Hoellwarth ME. Pisotriquetral arthrodesis for pisotriquetral instability: case report. J Hand Surg Am 2011;36 (02):299-303

27 Gaston RG, Lourie GM, Floyd WE III, Swick M. Pisotriquetral dysfunction following limited and total wrist arthrodesis. J Hand Surg Am 2007;32(09):1348-1355

28 Rancy SK, Trehan SK, Li AE, Lee SK, Potter HG, Wolfe SW. The prevalence of pisotriquetral arthritis in the setting of scapholunate advanced collapse. J Wrist Surg 2016;5(04):261-264

29 Yamaguchi S, Viegas SF, Patterson RM. Anatomic study of the pisotriquetral joint: ligament anatomy and cartilagenous change. J Hand Surg Am 1998;23(04):600-606

30 MoojenTM, Snel JG, Ritt MJPF, VenemaHW, den Heeten GJ, Bos KE. Pisiform kinematics in vivo. J Hand Surg Am2001;26(05):901-907

31 Rayan GM. Pisiform ligament complex syndrome and pisotriquetral arthrosis. Hand Clin 2005;21(04):507-517

32 Arya AP, Kulshreshtha R, Kakarala GK, Singh R, Compson JP. Visualisation of the pisotriquetral joint through standard portals for arthroscopy of the wrist: a clinical and anatomical study. J Bone Joint Surg Br 2007;89(02):202-205

33 McEwen S. Spain of the pisiform-triquetral joint. Report of 6 cases. J Bone Joint Surg. 1954;36B:618-621

34 Curtis RM, Engalitcheff J Jr. Awork simulator for rehabilitating the upper extremity-preliminary report. J Hand Surg Am1981;6(05): 499-501