




Available online at
 ScienceDirect
www.sciencedirect.com

Elsevier Masson France

www.em-consulte.com/en



WORKSHOPS OF THE SOO (2010, LA ROCHELLE). SYMPOSIUM: THE ARTHRITIC WRIST

The arthritic wrist. II - The degenerative wrist: Indications for different surgical treatments

J. Laulan^{a,*}, G. Bacle^a, C. de Bodman^a, N. Najihi^b, J. Richou^c, E. Simon^c,
Y. Saint-Cast^d, L. Obert^e, A. Saraux^f, P. Bellemère^g, T. Dréano^b,
M. Le Bourg^h, D. Le Nen^c

^a Service de chirurgie orthopédique 1 et 2, unité de chirurgie de la main, hôpital Trousseau, CHRU de Tours, 37044 Tours cedex, France

^b Service de chirurgie orthopédique, CHU hôpital sud, 35203 Rennes cedex 2, France

^c Service de chirurgie orthopédique, hôpital de la Cavale-Blanche, CHU de Brest, 29200 Brest, France

^d Centre de la main. 49100 Angers, France

^e Service de chirurgie orthopédique, hôpital Jean-Minjoz, CHU de Besançon, 25030 Besançon, France

^f Service de rhumatologie, hôpital de la Cavale-Blanche, CHU de Brest, 29200 Brest, France

^g Clinique Jeanne-d'Arc, 44100 Nantes, France

^h Centre hospitalier privé, 35768 Saint-Grégoire, France

KEYWORDS

Painful wrist;
Osteoarthritis;
Kienböck's disease;
SLAC wrist;
SNAC wrist

Summary For the patient (and the surgeon) the ideal wrist is one that has good mobility, however very often the optimal surgical treatment is one that provides effective pain relief. The patient must be informed of the potential complications and limitations of each procedure. The patient's psychological profile and functional requirements will determine how well he/she adapts to the changes. Also, each surgeon has beliefs and personal experiences that influence the treatment decision and final result. Proximal row carpectomy (PRC) and the Watson procedure are two reference operations for osteoarthritis secondary to scapholunate instability and scaphoid non-union (SLAC and SNAC). Beyond the early complications and drawbacks specific to each, they provide good results that are maintained over time. PRC, which can be performed up to Stage II, is mainly indicated in patients with moderate functional demands, while the Watson procedure is more often done on a patient who performs manual labour, as long as the radiolunate joint space is maintained. Complete denervation is effective in three out of four cases and preserves the remaining mobility. Because of its low morbidity, the procedure can be suggested in patients with a mobile wrist and low functional demands or in older patients, independent of their wrist mobility. Total wrist fusion is not only a rescue procedure. For a young patient who performs heavy manual labour with extensive osteoarthritis and progressive forms of Kienböck's disease, this procedure provides the greatest chance of returning to work and not being socially outcast. The role of osteochondral autografts, implants and wrist prostheses in the treatment arsenal need to be better defined.

© 2011 Elsevier Masson SAS. All rights reserved.

* Corresponding author. Tel.: +33 02 47 47 59 46.
E-mail address: j.laulan@chu-tours.fr (J. Laulan).

When faced with a painful, degenerative wrist, the different palliative surgical procedures can only be discussed after conservative treatment has failed.

The choice between surgical options is difficult to make because conclusions about the optimal procedure as a function of each radiological and clinical situation cannot be drawn from the published literature. In practice, the indication is often based on the surgeon's preferences and experience with a certain technique. The various participants in this work have reported good results with the palliative technique they use most often [1]. However, a review of the literature is not as favourable as results diverge widely, making it difficult to derive criteria on which to base procedure choices.

In practice, although the decision is based on the aetiology and extent of joint involvement, it is mostly influenced by the patient's functional demands and state of the wrist. As a consequence, we were interested in finding out what patients expected.

Survey of patients

To evaluate patients' wishes, two surveys were carried out by Charlotte de Bodman and Nabil Najihi. The first study, done prospectively, sought to define how patients viewed an ideal wrist. A questionnaire was given to patients who were being seen for a non-wrist injury to prioritize three parameters: pain, mobility and strength. The second study, done retrospectively, was given to patients after wrist surgery and sought to define what the main cause of dissatisfaction was after returning to work.

Among the 36 patients who responded to the questionnaire about the "ideal wrist", the priority was mobility for 48.5%, no pain for 34.8% and strength for 16.7%. Most of the patients were ready to give up strength to improve the result in terms of pain relief (73%) and mobility (83%); 59% were ready to give up some mobility to have less pain.

Among the 66 operated patients (68 wrists) who were satisfied (42%) or very satisfied (58%) with the result after an average follow-up of 50 months, the primary regret was the loss of mobility in 51% of cases. However the main cause of dissatisfaction was ongoing pain in 61.5% of cases, insufficient mobility in 27% of cases and insufficient strength in 11.5% of cases.

The desire for a mobile wrist is certainly in the forefront, as one of two patients regrets the loss of mobility after surgery. However, nearly 60% of patients are willing to give up mobility to have less pain and the persistence of pain is the main reason for dissatisfaction after a "successful" wrist operation. In a prospective study comparing full joint fusion and the Watson procedure, Wieloch et al. [2] found that the type of fusion did not affect satisfaction and that the pain relief parameter was more important to the patient than the mobility parameter. Thus, a procedure that maintains mobility should be favoured, but this mobility should not be achieved at any price, and pain reduction should not be compromised to preserve mobility.

Graham and Detsky used decision analysis for the treatment of early wrist arthritis and showed that the benefits produced by proximal row carpectomy (PRC) and the Watson procedure were slightly greater than a total joint fusion

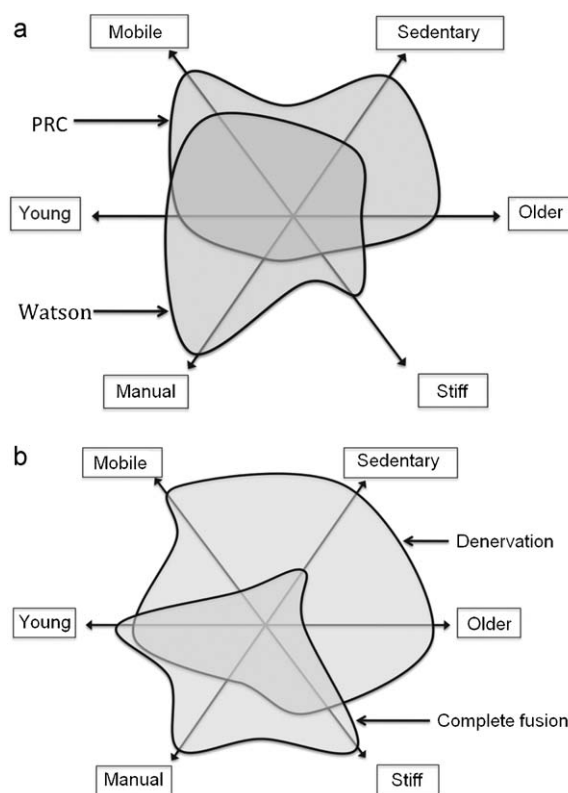


Figure 1 (a and b) Indications "areas" for the main surgical techniques as a function of background.

because mobility was preserved [3]. But they brought up a potential for residual pain in the remaining range of motion. These results only include early stages of arthritis; the potential for early failures after PRC and the appreciable number of complications after partial joint fusion should not be ignored. Finally, studies have shown that the results are not as good when a total joint fusion is performed after the early failure of a partial fusion [4–7].

Treatment choices and background

The choice of treatment mostly depends on the background: patient age (young vs. older), functional demands (manual labour vs. sedentary), and residual mobility of the wrist (mobile vs. stiff). Based on data in the literature and results provided by different surgeons, an attempt was made to align the main palliative procedures with the background (Figs. 1a and b). Significant overlap exists between the indications for the different techniques, resulting in multiple options to meet each patient's wishes and surgeon preference.

PRC can only be performed if the cartilage in the lunate fossa of the radius and head of the capitate are preserved. The indications could be extended to stage III SLAC and SNAC wrists by using an RCPI® resurfacing implant for the head of the capitate [8], however this approach must be validated over the medium and long term.

After PRC, we can expect that 80% of patients will be satisfied, with 2/3 of the mobility and 2/3 of the strength (50 to 100%) maintained, along with a DASH of about 25 (range

9 to 36). Although there is an early failure rate of 10 to 14% [9,10], mostly in younger patients [11], good results are seen in the long term, despite progressive degradation of the radio-capitate joint space being reported in 10 to 82% of cases.

PRC is simpler to execute and has fewer complications than the Watson procedure [12–14]. It preserves more of the mobility and gives similar results in terms of pain reduction and satisfaction for the patient. However, the risk of degenerative osteoarthritis is greater, especially in young, active patients, and strength is not as good [11,13]. Thus, this procedure is indicated in patients who are mostly sedentary, perform light manual labour [15], or are older and still have good mobility.

The results reported in the literature for the Watson procedure vary [16,17]. Although there is a reduction in pre-operative pain levels, complete pain relief only occurs in one of two cases and there are an appreciable number of complications. The rate of conversion to full wrist fusion is high in some series [17,18] and varies from 2 to 36%. Overall, the satisfaction rate was 80%, which is comparable to PRC. The procedure maintains 50% of the mobility on average and 75% of the strength, with a DASH ranging from 15 to 30.

When compared to PRC, the Watson procedure results in mobility that is not as good (50% vs. 66%) and more postoperative complications. Comparative studies show that PRC is better for stages 1 and 2 [18,19]. However, it tends to better restore strength (75% vs. 66%) with a lower risk of joint space degeneration [19] and have good long-term results [16,20]. This procedure is favoured in a person who performs heavy manual labour [15] and has partially preserved mobility, knowing that over time, younger subjects will have greater joint space narrowing [20].

Complete denervation can be performed even if the radiolunate joint space is altered. The procedure is not perfect but it gives useful long-term results, as it provides significant pain relief in 75 to 80% of patient, does not affect mobility, has few post-operative limitations (no immobilization) and none or few complications [21]. VAS is 2 to 3, strength is at 80% and the DASH between 25 and 30. The Brest and Tours series [1] confirmed that the results are not age-related, but that pain upon exertion is not uncommon and a patient who performs heavy manual labour may need to change jobs. In case of failure, the results of a potential surgical revision do not seem to be compromised. There are two broad types of indications: mostly sedentary patients of any age with good wrist mobility, and older patients, independent of their wrist mobility.

Total joint fusion is used as a rescue procedure after failure of another palliative intervention, but results are uncertain in this context, especially with an early failure [4,5,7]. Some patients indicated that they would have liked the total wrist fusion to be performed sooner because of the minimal benefit of the previous procedures [22]. However, we have previously shown [4,6] that if the total joint fusion is performed as a first-line treatment, it provide effective pain relief (VAS at 2), restores good strength (80 to 90%) and under these conditions, the majority of patients do not feel that the loss of mobility is a problem. It is indicated in a patient who performs heavy manual labour [23], has a stiff wrist and diffuse joint involvement. In a patient who has little or no possibility of retraining, it often allows a return to

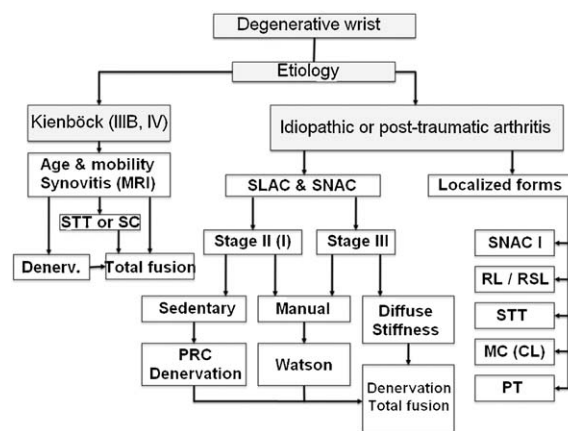


Figure 2 Decisional flow chart as a function of radiological data (treatment of localized forms are not described in detail). STT: scapho-trapezio-trapezoidal; SC: scaphocapitate; RL: radiolunate, RSL: radio-scapho-lunate; MC: mid-carpal; CL: capitulunate; PT: pisiform-triquetrum.

the same work or heavy manual labour. However, suggesting a total joint fusion to a sedentary and/or older patient does not seem justified if the patient still has good mobility, except in special cases.

Treatment choices and radiographs

The treatment choice is then based on the aetiology and extent of the arthritis. A decisional flow chart based specifically on radiology assessments of the radiolunate and capitulunate joint spaces, or even a CT scan of the joint, has been defined (Fig. 2). Kienböck's disease must be differentiated from other causes of wrist arthritis as it brings up specific problems.

Treatment indications in Kienböck's disease

Although good results can be obtained in Stage IIIB by shortening the radius [24], palliative treatment is most often needed when the disease has progressed. Even at this stage, some have suggested doing a scapho-trapezio-trapezoidal (STT) fusion [25] to unload the lunate, however this results in more failures than a total joint fusion and a complication rate of up to 40%, with 14% nonunion [26].

Data in the literature suggests that PRC provides inferior results in Kienböck's disease [9,12] and some authors no longer perform a PRC in this indication [10]. A synovitis exists in certain cases, suggestive of a true local-regional disease, which in our opinion could be responsible for the failure of conservative procedures.

As a consequence, two main procedures are relevant to the discussion: denervation and total joint fusion. Age, residual mobility and the presence of synovitis should be taken into account when choosing the treatment. In sedentary subjects with good mobility or in older patients, denervation avoids a lengthy immobilization and the potential complications related to fusion. In a young patient who performs heavy manual labour and has stage IIIB or IV disease, especially if synovitis is present, only fusion provides

reliable results. When the disease is in its later stages, Tambe et al. [27] have shown that total joint fusion provides better results than partial fusion, and like them, we believe that total joint fusion must be suggested early on in these forms. And Laurent Obert [1] has shown that in certain cases, a resection of the lunate with a rib cartilage graft may be appropriate.

Treatment indications for osteoarthritis due to scapholunate instability (SLAC wrist) or scaphoid non-union (SNAC wrist)

With stage II SLAC and SNAC wrists, three types of procedures should be considered: PRC, Watson procedure and complete denervation. The choice is mostly made as a function of the patient's age and functional demands. In a patient who is still working in manual labour, a Watson procedure seems the most logical, given that PRC or denervation may not result in effective pain relief in this context. PRC and denervation are possibilities in sedentary patients, depending on age, mobility and wishes, and knowing that a secondary PRC is still possible if the denervation fails early on. Here also, the Besançon team reported that an osteo-cartilage rib autograft can be used to replace the proximal pole of the scaphoid [28].

With stage III SLAC and SNAC wrists, a PRC is no longer an appropriate procedure [14]. At this stage, three factors must be taken into consideration: the radiolunate joint space, residual mobility and activity. Lane et al. [29] have recently reported that in cases of scapholunate dissociation, the radiolunate joint space is not always maintained and that a CT scan should be performed before considering a Watson procedure.

If the radiolunate joint space is totally maintained and there is good functional mobility in a patient who performs manual labour, it would be logical to perform a Watson procedure. Denervation is mostly indicated in a sedentary or older patient if preservation of mobility is a priority for the patient.

In diffuse affections involving the radiolunate joint space, choices include performing a primary total wrist fusion in a young patient who performs manual labour and denervation in a sedentary or older patient, especially if the wrist is stiff and/or very painful. Similarly, when a procedure designed to maintain mobility in an active subject fails, total joint fusion is indicated. In an older patient, a partial implant or even a total wrist joint replacement should be considered [1], either as primary intervention or if denervation fails.

Indications for localized osteoarthritis

Cases of localized arthritis include stage I SNAC, radiolunate or radio-scapho-lunate arthritis secondary to an articular radius fracture, STT arthritis, isolated midcarpal arthritis or pisiform-triquetrum arthritis.

For these types of arthritis, different procedures that are more or less location-specific should be considered: partial joint fusion, isolated resection arthroplasty or resection arthroplasty with interposition (tendon, partial implant, rib

cartilage). An autologous osteochondral graft can also be considered in the sequelae of die-punch fractures [30].

A simple resection of the pisiform can be carried out to treat pisiform-triquetrum osteoarthritis after failure of conservative treatment [31].

Conclusions

Although a mobility-preserving procedure is favoured, it should not be done at any price, since the preservation of a certain amount of wrist mobility is not essential to good upper limb function [32].

The aetiology and stage of the arthritis allows certain procedure choices to be eliminated, but the final choice is based on residual wrist mobility, the patient's wishes, functional demands and potential for job retraining.

PRC is mainly indicated in a middle-aged patient, even elderly who has good mobility and moderate functional demands. The Watson procedure is mostly indicated in a person who performs manual work, is not too old and still has some mobility. Because of its low morbidity, complete denervation can be suggested in patients with a mobile wrist and low functional demands or in older patients, independent of their wrist mobility. Total wrist fusion is mostly indicated in young patients who perform heavy manual labour, especially if the wrist is already stiff.

The role of osteochondral autografts, implants and wrist prostheses in the treatment arsenal needs to be better defined.

Disclosure of interest

The authors declare that they have no conflicts of interest concerning this article.

References

- [1] Le Nen D, et al. Le poignet dégénératif: les méthodes thérapeutiques. *Rev Chir Orthop*.
- [2] Wieloch PT, Martini AK, Jung M, Daecke W. Long-term results after mediocarpal and total arthrodesis of the wrist: a matched paired study. *Z Orthop Ihre Grenzgeb* 2006;144:206–11.
- [3] Graham B, Detsky AS. The application of decision analysis to the surgical treatment of early osteoarthritis of the wrist. *J Bone Joint Surg* 2001;83B::650–4.
- [4] Bazelli R, Lascar T, Laulan J. Arthrodèses du poignet: partielles ou totales? *Chir Main* 2000;19:331.
- [5] Chantelot C, Becquet E, Lecomte F, Lahoude-Chantelot S, Prodomme G, Fontaine C. Étude rétrospective de 13 arthrodèses scaphocapitatum pour instabilité scapholunaire chronique. *Chir Main* 2005;24:79–83.
- [6] Hérard J, Cohen G, Baclet G, Laulan J. Résultats des arthrodèses totales du poignet par plaque dédiée. À propos de 30 cas évalués à 5 ans de recul. *Chir Main* 2008;27:283–4.
- [7] McAuliffe JA, Dell PC, Jaffe R. Complications of intercarpal arthrodesis. *J Hand Surg* 1993;18A:1121–2118.
- [8] Marcuzzi A, Russomando A, Gabrieli R. Expérience personnelle sur la résection de la première rangée du carpe associée à l'application de la prothèse RCPI pour la tête du grand os. *Chir Main* 2009;28:424.
- [9] De Smet L, Robijns P, Degreef I. Proximal row carpectomy in advanced Kienbock's disease. *J Hand Surg* 2005;30B:585–7.

- [10] Schernberg G. La résection arthroplastique de la première rangée des os du carpe. Communication personnelle. Les lésions articulaires traumatiques du membre supérieur chez l'adulte. Symposium de l'Institut de la Main, Paris, 3 et 4 mai 2010.
- [11] DiDonna ML, Kiefhaber TR, Stern PJ. Proximal row carpectomy: Study with a minimum of 10 years of follow-up. *J Bone Joint Surg* 2004;86A(11):2359–65.
- [12] Lecomte F, Wavreille G, Limousin M, Strouk G, Fontaine C, Chantelot C. Proximal row carpectomy: 25 cases. *Rev Chir Orthop* 2007;93:444–54.
- [13] Richou J, Chuinard C, Moineau G, Hanouz N, Hu W, Le Nen D. Proximal row carpectomy: long-term results. *Chir Main* 2010;29:10–5.
- [14] Tomaino MM, Miller RJ, Cole I, Burton RI. Scapholunate advanced collapse wrist: proximal row carpectomy or limited wrist arthrodesis with scaphoid excision? *J Hand Surg* 1994;19A:134–42.
- [15] Dacho AK, Baumeister S, Germann G, Sauerbier M. Comparison of proximal row carpectomy and midcarpal arthrodesis for the treatment of scaphoid nonunion advanced collapse (SNAC-wrist) and scapholunate advanced collapse (SLAC-wrist) in stage II. *J Plast Reconstr Aesthet Surg* 2008;61:1210–8.
- [16] Bain GI, Watts AC. The outcome of scaphoid excision and four corner arthrodesis for advanced carpal collapse at a minimum of ten years. *J Hand Surg* 2010;35A:719–25.
- [17] Siegel JM, Ruby LK. Midcarpal arthrodesis. *J Hand Surg* 1996;21A:179–82.
- [18] Wyrick JD, Stern PJ, Kiefhaber TR. Motion-preserving procedures in the treatment of scapholunate advanced collapse wrist: proximal row carpectomy versus four-corner arthrodesis. *J Hand Surg* 1995;20A:965–70.
- [19] Mulford JS, Ceulemans LJ, Nam D, Axelrod TS. Proximal row carpectomy vs four corner fusion for scapholunate (Slac) or scaphoid nonunion advanced collapse (Snac) wrists: a systematic review of outcomes. *J Hand Surg* 2009;34E:256–63.
- [20] Le Bourg M, Raimbeau G, Belot N, Dos Remedios C, Saint-Cast Y, Fouque PA. Four bone fusion associated with scaphoidectomy: greater than ten years follow-up results from a retrospective study of 43 consecutive cases. Congrès de la FESSH, Lausanne, 19–21 juin 2008.
- [21] Foucher G, Da Silva JB. Denervation of the wrist. *Ann Chir Main Memb Super* 1992;11(4):292–5.
- [22] Sagerman SD, Palmer AK. Wrist arthrodesis using a dynamic compression plate. *J Hand Surg* 1996;21B:437–41.
- [23] Fuchs S, Achinger R. Outcome of total arthrodesis of the hand. *Unfallchirurg* 1995;98:350–4.
- [24] Altay T, Kaya A, Karapinar L, Ozturk H, Kayali C. Is radial shortening useful for Lichman stage 3B Kienbock's disease? *Int Orthop* 2008;32:747–52.
- [25] Nakamura R, Horii E, Watanabe K, Nakao E, Kato H, Tsunoda K. Proximal row carpectomy versus limited wrist arthrodesis for Advanced Kienböck's disease. *J Hand Surg* 1998;23B:741–5.
- [26] Larsen CF, Jacoby RA, McCabe SJ. Nonunion rates of limited carpal arthrodesis: a meta-analysis of the literature. *J Hand Surg* 1997;22A:66–73.
- [27] Tambe AD, Trail IA, Stanley JK. Wrist fusion versus limited carpal fusion in Advanced Kienbock's disease. *Int Orthop* 2005;29:355–8.
- [28] Lepage D, Obert L, Clappaz P, Hampel C, Garbuio P, Tropet Y. Traitement de l'arthrose radio-scaphoïdienne par résection proximale du scaphoïde et autogreffe osteocartilagineuse costale. *Rev Chir Orthop* 2005;91:307–13.
- [29] Lane LB, Daher RJ, Leo AJ. Scapholunate dissociation with radiolunate arthritis without radioscapoid arthritis. *J Hand Surg* 2010;35A:1075–81.
- [30] Obert L, Lepage D, Tropet Y, Garbuio P. Cal vicieux articulaire du radius distal avec arthrose radio carpienne traité par greffon chondro costal. In: Dubrana F, Lefevre C, Le Nen D, editors. *Trucs et astuces en chirurgie orthopédique et traumatologique*, T4. Montpellier: Sauramps Médical; 2006. p. 331–8.
- [31] Pierre A, Le Nen D, Hu W, Dubrana F, Saraux A, Chaise F. Traitement des douleurs piso-triquétrales par exérèse du pisiforme: à propos de 15 cas. *Chir Main* 2003;22:37–42.
- [32] Weiss AC, Wiedeman Jr G, Quenzer D, Hanington KR, Hastings 2nd H, Strickland JW. Upper extremity function after wrist arthrodesis. *J Hand Surg* 1995;20A:813–7.