Abord postéro-médial du tibia…porte ouverte sur 5 familles de lambeaux

Dominique Le Nen*, Nathalie Kerfant**, Hoël Letissier*
Alexandra Trimaille**, Anne-Sophie Henry**, Weiguo Hu**

** Service de Chirurgie Orthopédique, Traumatologique et Réparatrice - CHU BREST*
*** Service de Chirurgie Plastique, Reconstructrice et Esthétique - CHU BREST*

Congrès de la SOO – RENNES , 28 – 30 juin 2018

1 – Lambeaux FC péninsulaires
2 – Lambeaux FC bipédiculés
3 – Perforator flaps FC (axe TP)
4 – Lambeaux fascio-graisseux
5 – Lambeaux musculaires

- Point commun = abord postéro-médial unique, un centimètre en arrière du tibia (= voie du débridement)

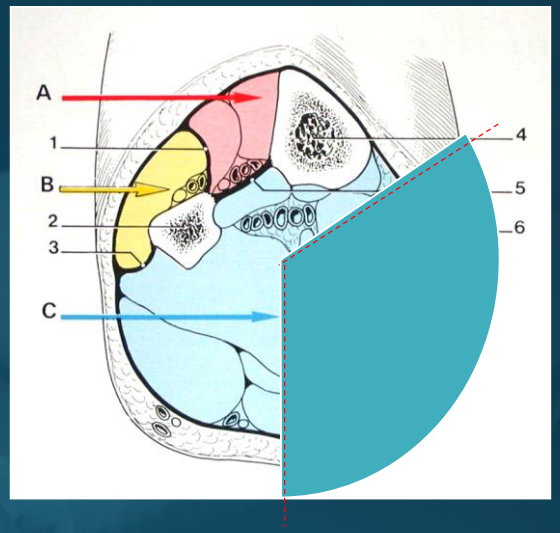

- Concept :

- lambeaux à la carte (→ 5 familles)
- voire choix per-opératoire
- surtout lambeaux fascio-cutanés +++

- Indications :

Pertes de substance cutanée pré-tibiales, du genou à la cheville

Fractures ouvertes ++

1 – Lambeaux FC péninsulaires

Lambeau FC médial à charnière proximale

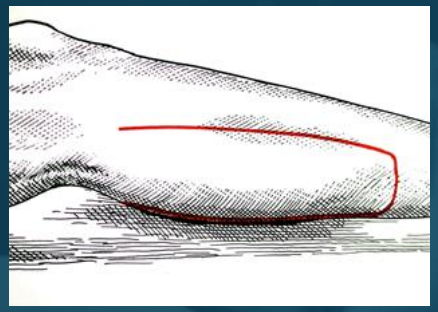

Lambeau FC médial à charnière distale

translation
rotation
retournement

2 – Lambeaux FC bipédiculés

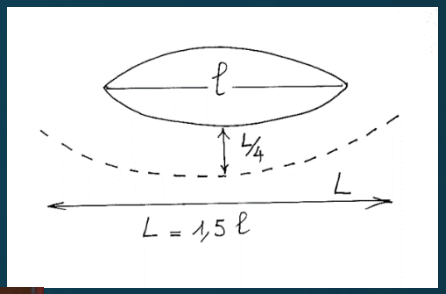

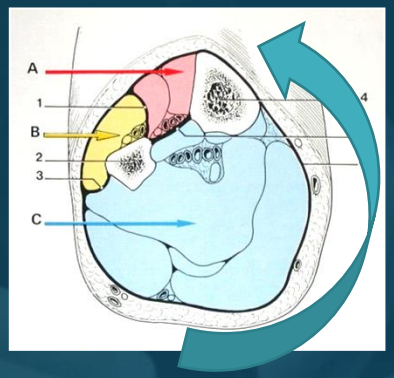

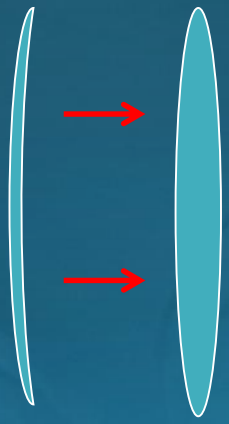

3 - Perforator flap FC (axe TP)

El-Saadi MM, Khashaba AA. Three amteromedial fasciocutaneous leg island flaps for covering defects of the lower two-thirds of the leg. *Br J Plast Surg 1990*

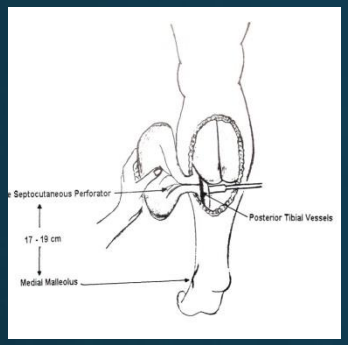

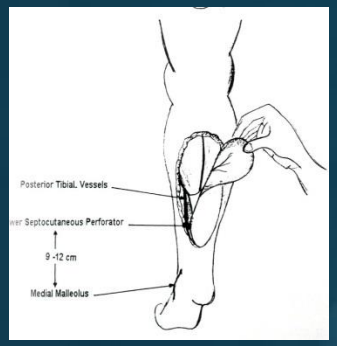

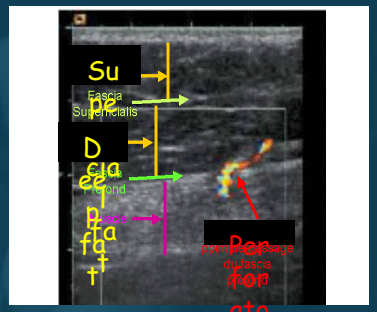

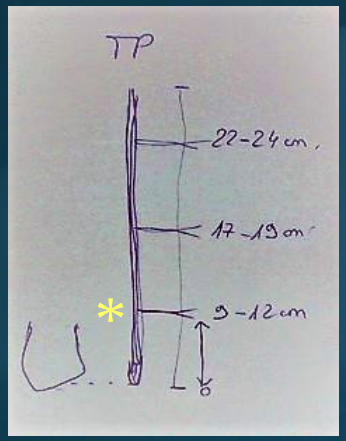

Lambeau à pédicule perforant distal
levé sur l'axe TP
9 – 12 cm

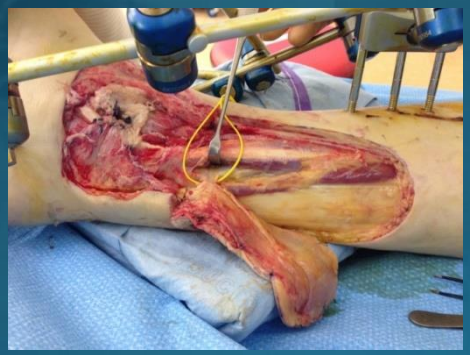

4 – Lambeaux fascio-graisseux

Labo Anatomie BREST

Heymans O, Verhelle N, Peter S. **The medial adiposofascial flap of the leg: anatomical basis and clinical applications.** *Plast Reconstr Surg 2005*

5 – Lambeaux musculaires

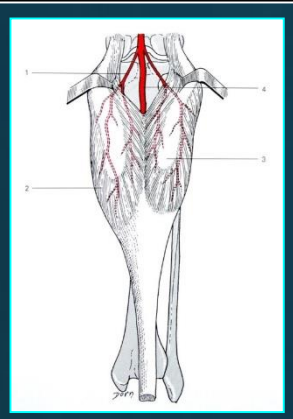

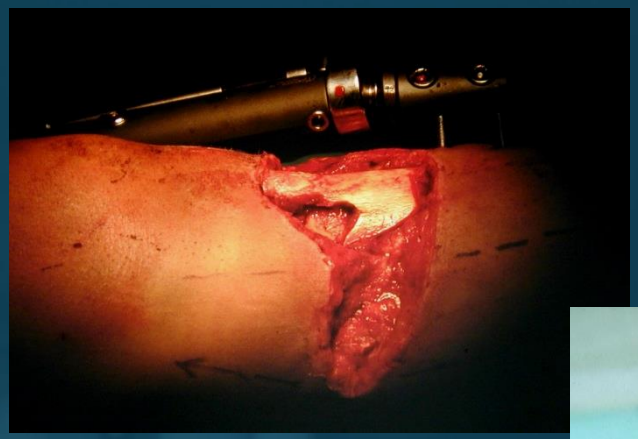

Gastrocnémien médial

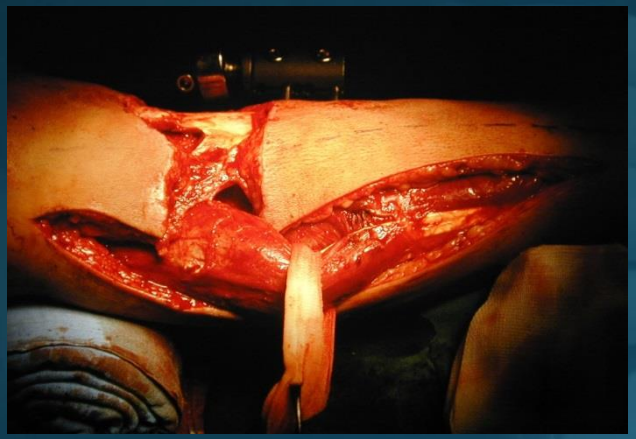

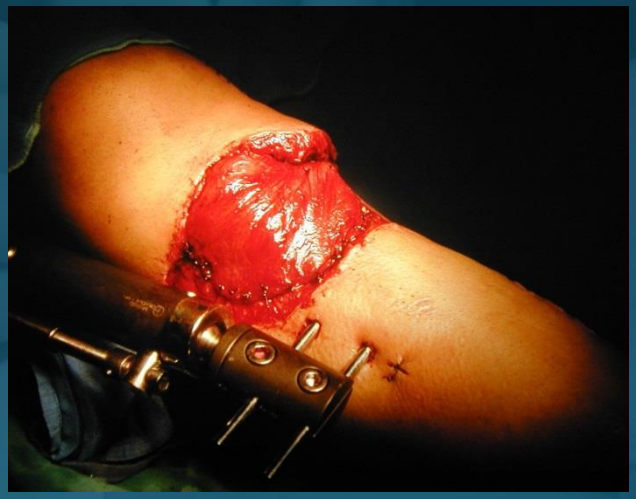

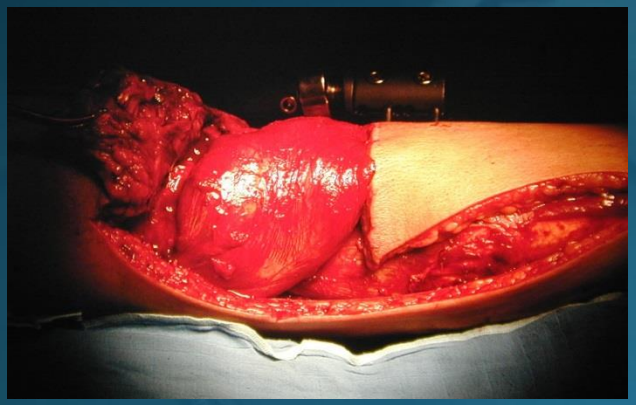

Soleus médial

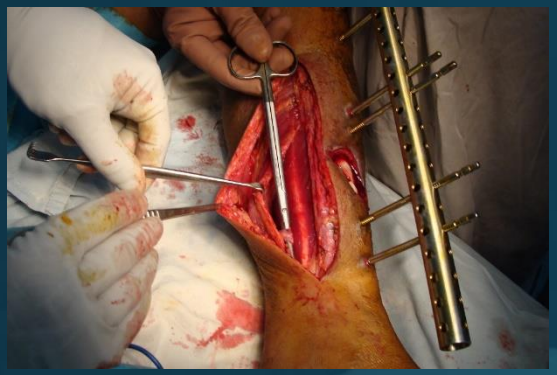

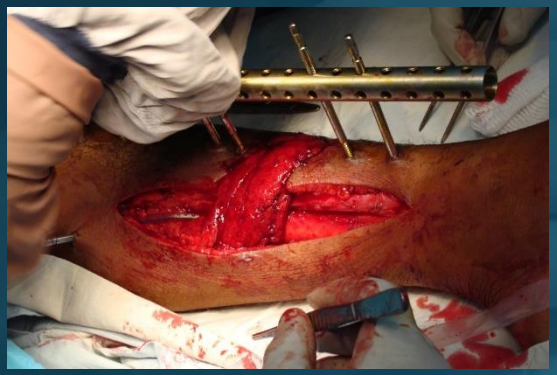

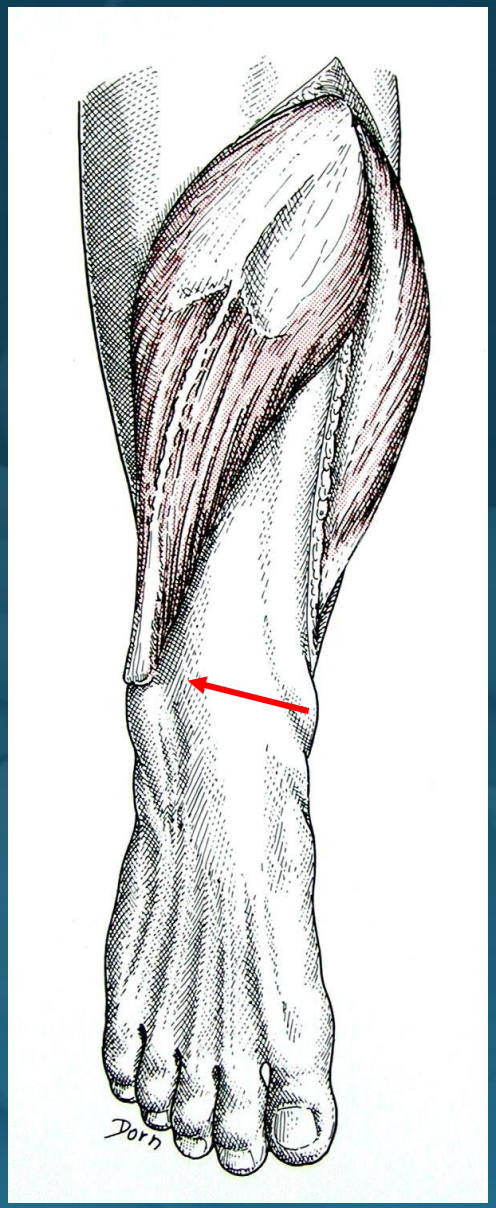

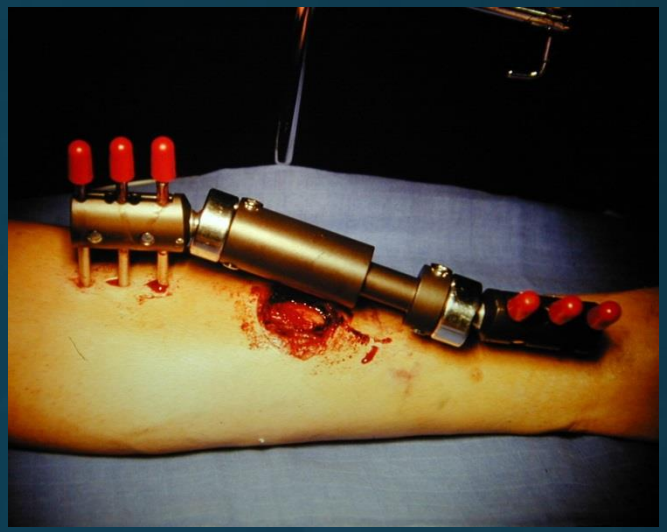

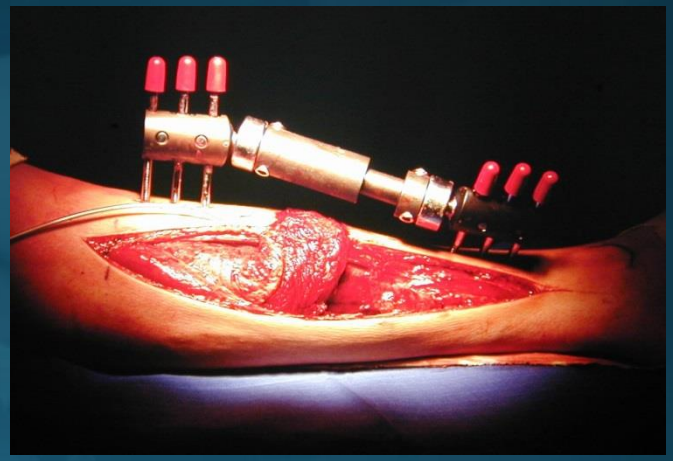

Abord postéro-médial du tibia…

En synthèse… *porte ouverte sur 5 familles de lambeaux*

1 – Lambeaux FC péninsulaires
2 – Lambeaux FC bipédiculés
3 – Perforator flaps FC (axe TP)
4 – Lambeaux fascio-graisseux
5 – Lambeaux musculaires

Lambeaux musculaires

Lambeaux FC péninsulaires

Lambeaux fascio-graisseux

Lambeaux perforants

Lambeaux bipédiculés

Conclusion

*Take home message

1 – Un fixateur externe sera posé en épargnant les deux faces cutanéo-musculaires du segment jambier : postéro-médiale et antéro-latérale

2 - Aucune dissection « au doigt » sous-fasciale → lésions définitives des perforantes

3 – Une majorité des fractures ouvertes de jambe peut être couverte par des lambeaux pédiculés

4 – Approche ortho-plastique de la reconstruction osseuse

Boucher F, Mojallal A. Atlas des artères perforantes de la peau, du tronc et des membres. Elsevier Masson, 2015
El-Saadi MM, Khashaba AA. Three anteromedial fasciocutaneous leg island flaps for covering defects of the lower 2/3 of the leg. Br J Plast Surg 1990
Heymans O, Verhelle N, Peter S. The medial adiposofascial flap of the leg: anatomical basis and clinical applications. Plast Reconstr Surg 2005
Le Nen D, Fabre A, Dubrana F. Réparation tissulaire à la jambe: de l'os à la peau. Springer, 2012
Masquelet AC , Gilbert A : Chirurgie réparatrice en orthopédie-traumatologie. Tome 1 : Les Lambeaux, Sauramps Medical, 2010